

# Automatic Diagnosis of Spasmodic Dysphonia with Structural MRI and Machine Learning

Davide Valeriani, PhD<sup>1</sup> and Kristina Simonyan, MD, PhD<sup>1</sup>

<sup>1</sup>Harvard Medical School, Boston, MA, USA

## Introduction

Spasmodic dysphonia (SD) is a neurologic disorder of unknown causes and pathophysiology. SD is characterized by involuntary spasms in the laryngeal muscles that are specific to speech production. Highly variable symptomatology and the absence of objective diagnostic criteria make the diagnosis of SD challenging, leading to misdiagnosis and delayed treatment. As neuroimaging studies described SD-specific brain abnormalities contributing to its pathophysiology (Simonyan et al., 2012; Battistella et al., 2016), the aim of this study was to use a series of machine-learning algorithms to identify automatic objective diagnostic markers of SD based on structural abnormalities.

## Methods

Whole-brain T1-weighted MRI images of 52 SD patients (53.9±9.5 years, 33 females) and 52 age/gender-matched healthy controls (52.5±10.0 years, 33 females) were acquired on a 3T scanner. In each subject, FreeSurfer was used to extract cortical thickness (CT) and SPM12 CAT toolbox was used to extract gray matter volume (GMV). The performance of four classifiers was examined: (1) linear discriminant analysis (LDA), (2) linear support vector machines (SVM) with regularization strength  $C=100$ , (3) neural network (NN) with one hidden layer of 12 neurons, logistic activation, and Adam optimizer, and (4) an ensemble of convolution neural networks (CNNs).

For LDA, SVM and NN feature selection, we performed a separate meta-analysis (GingerALE) of previous imaging studies that applied voxel-based morphometry and CT analyses in SD patients and healthy controls (Simonyan et al., 2012; Kostic et al., 2016; Termsarasab et al., 2016; Waugh et al., 2016; Bianchi et al., 2017; Kirke et al., 2017). Meta-analysis found six clusters at the voxel-wise significance level of  $p=0.001$  and minimum cluster volume of 200 mm<sup>3</sup>. Using these clusters as a mask, the average CT and GMV measures were extracted, resulting in a total of 12 structural features per subject. The performance of LDA, SVM and NN was computed using a 13-fold cross-validation.

For CNN, the whole-brain GMV and CT images were subsampled by a factor of 2 and split into training (78 subjects) and test (26 subjects) sets. Data were augmented by extracting volumetric patches of 25x25x25 from each image. We trained two CNNs (Figure 1) with Keras, one with CT images and one with GMV images. The outputs of the two CNNs were then averaged across patches associated to the same subject and across CNNs to obtain the ensemble prediction.

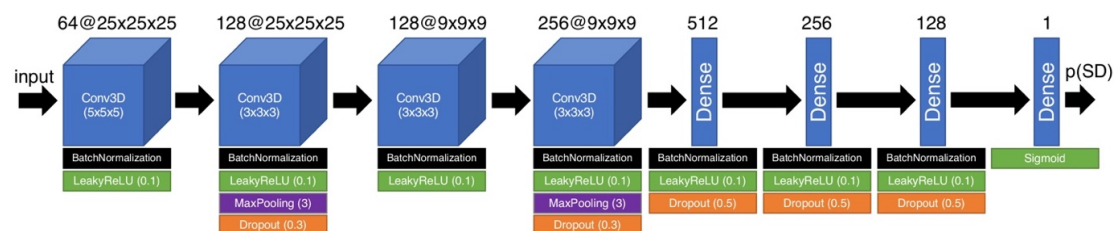


Figure 1. Architecture of the CNN.

## Results

Meta-analysis of VBM and CT literature in SD patients vs. healthy controls found significant structural abnormalities mainly present in the left hemisphere, including premotor cortex (#2), putamen (#3), inferior parietal cortex (#4), and inferior frontal gyrus (#5) (Figure 2). Clusters in the primary motor cortex (#1 and #6) were found bilaterally.

Based on these data, the combination of CT and GMV features resulted in average cross-validation AUC of 72.6% for LDA, 70.2% for SVM, 66.4% for NN, and 53.3% for CNN.

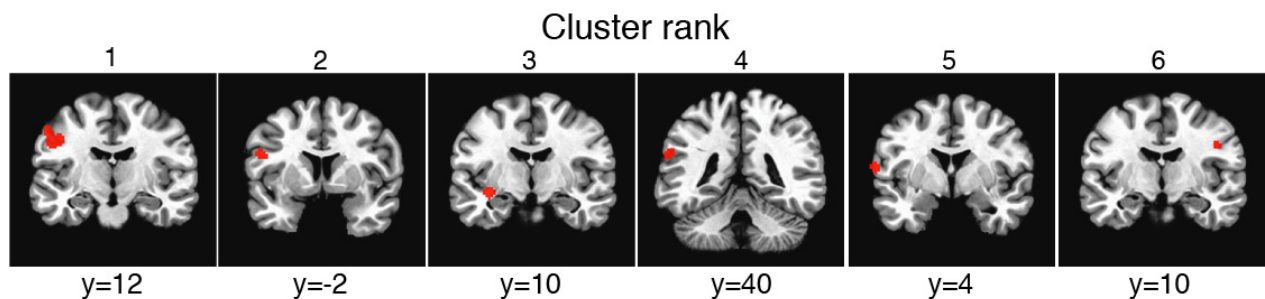


Figure 2. Coronal slices in standard Talairach-Tournoux space with clusters of significant abnormalities between SD patients and healthy controls identified by meta-analysis.

## Conclusions

Machine-learning classifiers based on meta-analysis driven disorder-specific brain abnormalities correctly diagnosed SD in approximately two out of three patients, showing their strong translational potential in contrast to clinical evaluation of dystonic symptoms with a 34% agreement rate among expert physicians (Ludlow et al., 2018). LDA outperformed other algorithms and also showed superior performance to LDA applied to resting-state fMRI in SD patients (Battistella et al., 2016). This suggests that a combination of supervised structural feature selection and LDA may be a promising avenue for the development of objective tools for SD diagnosis. CNN suffered from underfitting due to the small dataset. Taken together, structural brain abnormalities identified in SD could serve as imaging markers for objective diagnosis of this disorder. Future work should focus on integrating features extracted from other imaging modalities (e.g., fMRI) in the classification pipeline.

## References

- Battistella G, Fuertinger S, Fleysher L, Ozelius LJ, Simonyan K (2016) Cortical sensorimotor alterations classify clinical phenotype and putative genotype of spasmodic dysphonia. *European Journal of Neurology* 23:1517-1527.
- Bianchi S, Battistella G, Huddleston H, Scharf R, Fleysher L, Rumbach AF, Frucht SJ, Blitzer A, Ozelius LJ, Simonyan K (2017) Phenotype- and genotype-specific structural alterations in spasmodic dysphonia. *Mov Disord* 32:560-568.
- Kirke DN, Battistella G, Kumar V, Rubien-Thomas E, Choy M, Rumbach A, Simonyan K (2017) Neural correlates of dystonic tremor: a multimodal study of voice tremor in spasmodic dysphonia. *Brain Imaging Behav* 11:166-175.
- Kostic VS, Agosta F, Sarro L, Tomic A, Kresojevic N, Galantucci S, Svetel M, Valsasina P, Filippi M (2016) Brain structural changes in spasmodic dysphonia: A multimodal magnetic resonance imaging study. *Parkinsonism Relat Disord* 25:78-84.

Ludlow CL, Domangue R, Sharma D, Jinnah HA, Perlmutter JS, Berke G, Sapienza C, Smith ME, Blumin JH, Kalata CE, Blindauer K, Johns M, Hapner E, Harmon A, Paniello R, Adler CH, Crujido L, Lott DG, Bansberg SF, Barone N, Drulia T, Stebbins G (2018) Consensus-Based Attributes for Identifying Patients With Spasmodic Dysphonia and Other Voice Disorders. *JAMA Otolaryngol Head Neck Surg* 144:657-665.

Simonyan K, Ludlow CL (2012) Abnormal structure-function relationship in spasmodic dysphonia. *Cereb Cortex* 22:417-425.

Termsarasab P, Ramdhani RA, Battistella G, Rubien-Thomas E, Choy M, Farwell IM, Velickovic M, Blitzer A, Frucht SJ, Reilly RB, Hutchinson M, Ozelius LJ, Simonyan K (2016) Neural correlates of abnormal sensory discrimination in laryngeal dystonia. *Neuroimage Clin* 10:18-26.

Waugh JL, Kuster JK, Levenstein JM, Makris N, Mulhaupt-Buell TJ, Sudarsky LR, Breiter HC, Sharma N, Blood AJ (2016) Thalamic Volume Is Reduced in Cervical and Laryngeal Dystonias. *PLoS One* 11:e0155302.

### **Keywords**

Machine Learning

Movement Disorder

Structural MRI

Other - Dystonia